



Hermit Park Clinic

& Skin Cancer Care

Dr Greg Canning

222 Charters Towers Road

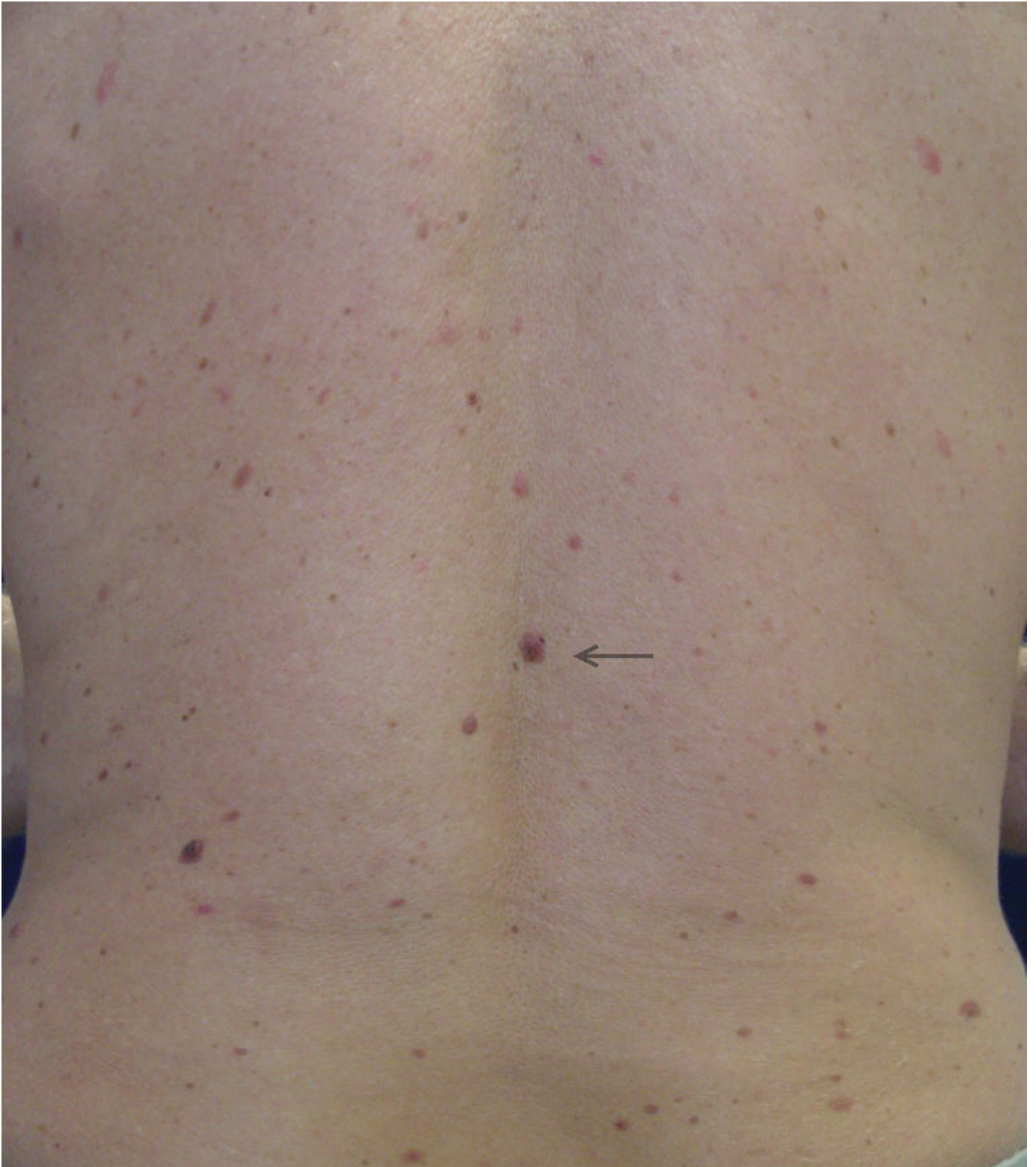Hermit Park Qld 4812

Ph 07 47 255 355

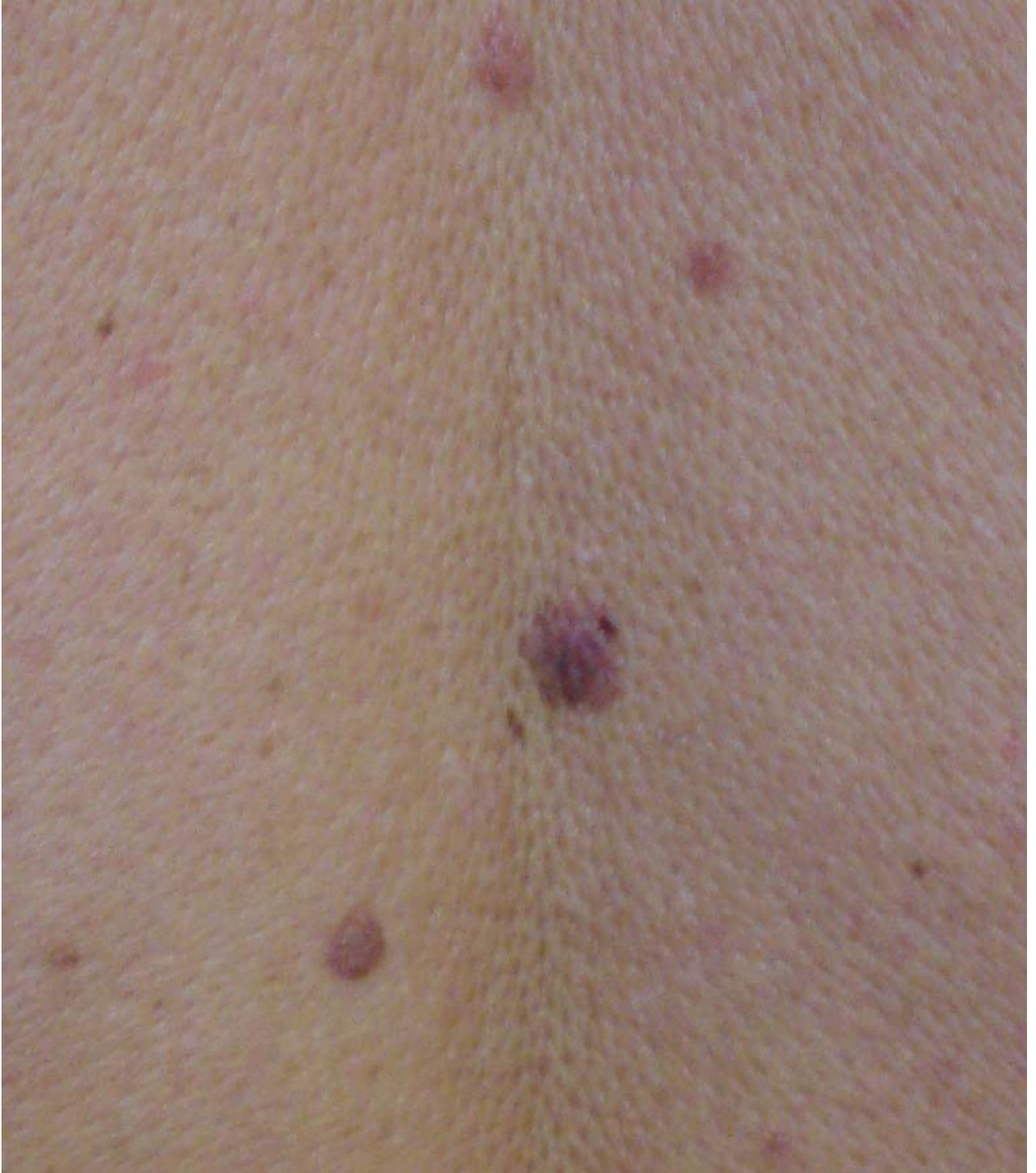gregcanning@hermitparkclinic.com

Example Dermoscopy Report

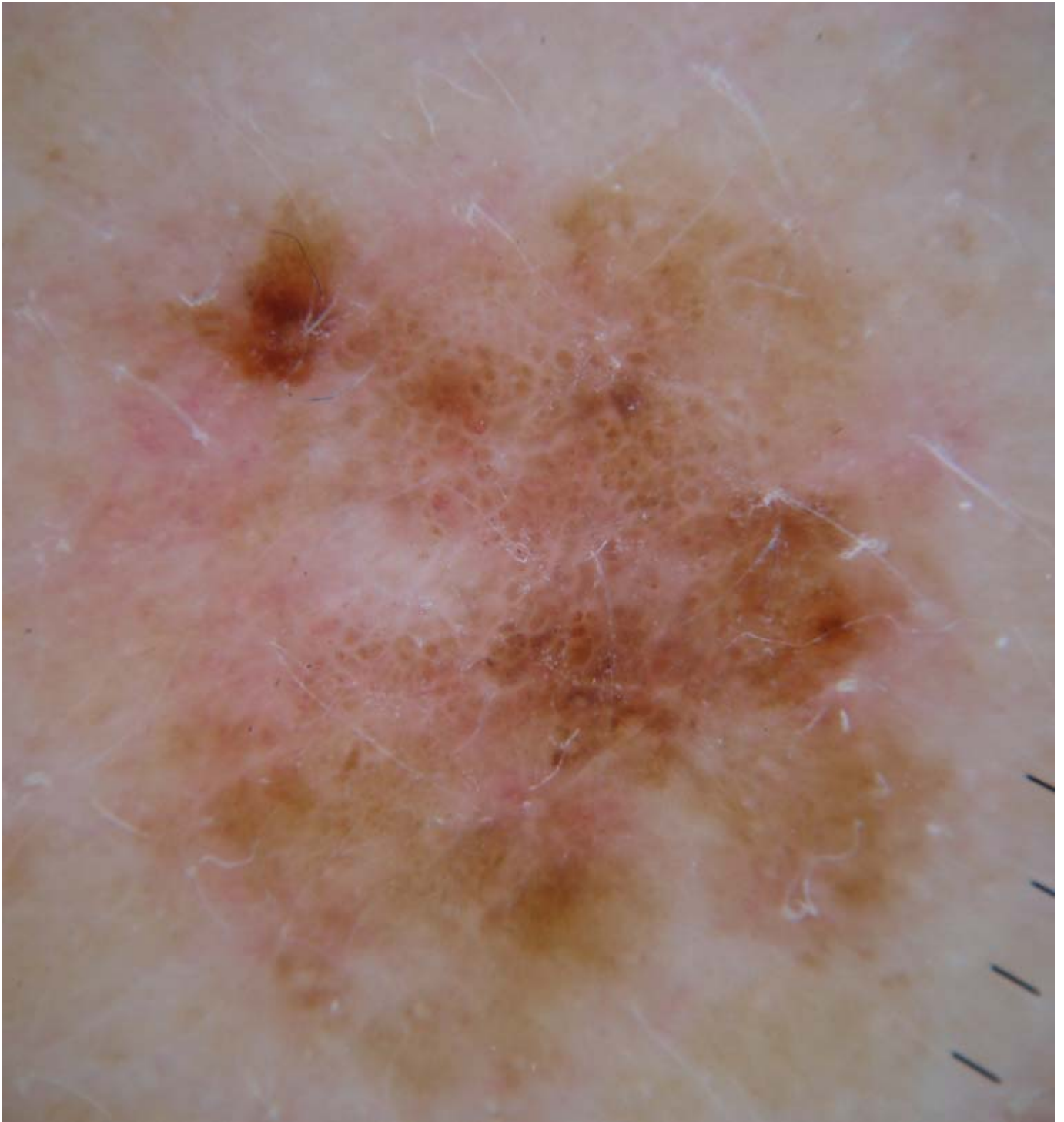
Patient Details		Date: 24 Dec 2007
Name	Mr. P. Xxxxx	
Age	42	
Occupation	Carpenter	
Skin photo-type	Type III	
History- Self	5 previous BCC's excised, no history of melanoma	
-Family	Nil	
Number of Nevi	> 100	
Atypical Nevi	2	
History of Lesion		
Changing :	Nil – detected on routine screening	
Symptoms:	Nil	
Clinical Description		
Location	Back over spine of T10	
Asymmetry	in 2 axes	
Borders	irregular	
Colours	3	
Size	9x8 mm	
Macule/ papule/ nodule	Macule with papular areas	
Ulceration	Nil	
Ugly-duckling	yes	
Two Step Algorithm	Criteria for melanocytic lesion: pigment network and globules Criteria for non-melanocytic lesion: no	
Algorithm Used	Pattern Analysis	
Dermoscopic Features	4 Colours, Biaxial Asymmetry, reticulo-globular disorganized pattern, Local features : reticular depigmentation (inverse network), scar like regression, blotches irregularly distributed	
Equipment Used	Sony Cybershot DSC-W55 and Dermlite Pro Hybrid	
Images	See attached	
Diagnosis	Melanoma , DDx Dysplastic Nevus	
Management Recommendation	Excision Biopsy	
Comment for Pathologist	Nil	



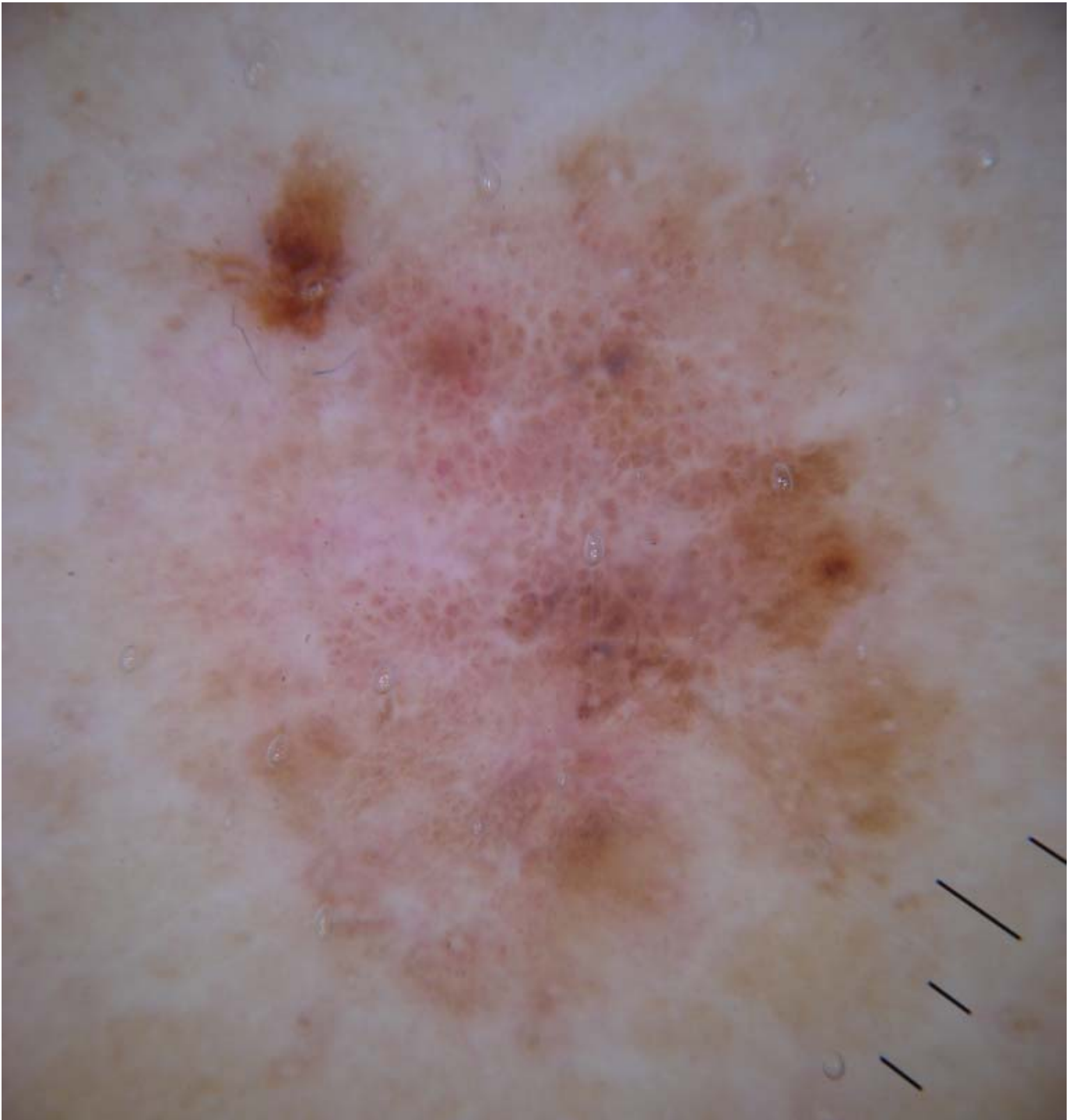
1. Clinical Photograph



2. Macro Photograph



3. Dermoscopic Photograph (Dermlite Pro Hybrid – polarized mode)



4. Dermoscopic Photograph (Dermlite Pro Hybrid – non polarized mode)

Excision Biopsy was performed and revealed: MALIGNANT MELANOMA IN-SITU OF SUPERFICIAL SPREADING TYPE. (CLARK LEVEL 1). NEAREST LATERAL MARGIN 1.5MM.

Formal re-excision was undertaken to achieve 5 mm margins as recommended by the NHMRC.